

Detection Of Microsporidiosis In Cases With Chronic Renal Failure

Hanaa Omar Fadl¹, Safaa Abd El-wahed El-Gabrty², Nihal Ahmed Hanafy³, Hosni Khairy Salem⁴, Nadia Ali El dib⁵

¹ Lecturer Assistant of Parasitology, Faculty of Medicine, Cairo University, Egypt.

² Lecturer of Chemical Pathology, Faculty of Medicine, Cairo University, Egypt.

³ Lecturer of Parasitology, Faculty of Medicine, Cairo University, Egypt.

⁴ Professor of Urosurgery, Faculty of Medicine, Cairo University, Egypt.

⁵ Professor of Parasitology, Faculty of Medicine, Cairo University, Egypt.

Email addresses: hanaomar_3@yahoo.com¹, safaaelgabrty@yahoo.com², nihal.hanafy@gmail.com³,
dr_hosni@yahoo.com⁴ and naeldib@hotmail.com⁵

Corresponding Author: Safaa Abd El-wahed El-Gabrty

ABSTRACT: Patients with chronic renal failure (CRF) undergoing hemodialysis are individuals whose immune system is significantly compromised rendering them susceptible to infection by opportunistic organisms. The aim of the work was to detect microsporidial infection in stool and urine samples from chronic renal failure patients using conventional microscopy with Modified Trichrome Stain (MTS) and molecular methods using Polymerase Chain Reaction (PCR). A cross sectional study was performed on 80 subjects including study group (n=50, CRF patients) and control group (n=30, apparently healthy volunteers). Fresh stool and urine samples from both groups are taken. All stool and urine samples were subjected to parasitological examination and molecular diagnosis. Each stool sample will be examined by microscopy as direct smear for other parasites and Permanent stained smears using (MTS) (Weber Green) for detection of microsporidia spores and subjected to molecular diagnosis by (PCR). The sediment of all urine samples was divided into two parts; the first part was examined by microscopy as Permanent stained smears using (MTS) (Weber Green) for detection of microsporidia spores. The second part will be stored at - 20 c° in eppendorf tubes for molecular diagnosis by PCR. PCR was used as a confirmatory test after MTS for the detection of DNA of microsporidia in stool and urine specimens. In the study group (n=50), microsporidiosis was revealed in 2 stool samples (4%) using both PCR and Modified Trichrome stain. One stool sample was positive only by MTS staining. No microsporidia spores were detected in the urine samples or the control group.

Keywords-Chronic renal failure, Immunocompromized patients, Microsporidia, Molecular diagnosis, Opportunistic infection.

I. INTRODUCTION

Microsporidia are recognized as opportunistic infectious agents distributed worldwide in both developed and developing countries. Human microsporidiosis represents an important disease, occurring mainly but not exclusively in immunocompromised individuals [1, 2].

Immunosuppressed hosts are more likely to acquire infection after exposure, have more severe disease once the infection is established, have disseminated infection rather than localized infection [3].

Microsporidia are a unique group of obligate intracellular unicellular eukaryotic parasites belonging to the phylum Microspora that form spores and have a unique mechanism of host cell infection. They infect a wide range of eukaryotic cells in numerous invertebrate and vertebrate hosts [4].

There are more than 1300 species and 150 genera of microsporidia that are characterized by their diverse structural, physiological, and genetic characteristics that transcend borders of traditional taxonomical classification, making it difficult to place them in any one category [5].

Fourteen species are implicated in human pathology, including *Enterocytozoon bieneusi* and *Encephalitozoon intestinalis* [4].

The majority of microsporidian infections in mammals are believed to occur through ingestion or inhalation of spores. [6].

Microsporidial infections in immunocompetent patients are often asymptomatic or self-limited while in immunocompromised patients may result in a lethal disease [4].

Methods of diagnosis of infection with microsporidia depend on detection of the spores in tissue biopsies, urine, sinus aspirates, nasal mucus, bronchoalveolar lavage or stool. A variety of methods are used to detect microsporidia. The diagnostic practices include use of microscopy and staining methods, immunological methods and polymerase chain reaction (PCR) [7].

Microscopic examination of stool specimens allows diagnosis of microsporidial infections but does not allow accurate species determination, which is important for medical therapy [8].

Thus, PCR-based methods have been successfully used for microsporidia species detection and differentiation [9].

II. SUBJECT AND METHODS:

A total of 80 subjects, including study group (n=50) and control group (n=30) are examined for the presence of Microsporidia. The number of 50 patients with chronic renal failure of both sexes (attending renal dialysis units and inpatient-sections of Kasr Al-Aini, Faculty of Medicine, Cairo University) were chosen for this study. Fresh fecal and urine specimens were collected from both groups included in the study. Samples were collected in dry, clean, wide-mouth plastic containers with tight-fitting lids. A data collection sheet containing demographic, clinical and laboratory data was obtained with each sample.

All stool and urine samples were subjected to the following:

Parasitological examination: examination of samples for detection of microsporidia or other parasites.

Molecular diagnosis: DNA extraction of microsporidia from frozen stool and urine samples followed by the PCR technique.

2.1. Parasitological examination:

2.1.1. Stool samples:

Stool samples were divided into:

* A small part of specimen for direct wet smear examination (in case of diarrheal sample).

* Part preserved in 10% formalin for subsequent concentration using formalin-ethyl acetate sedimentation procedure to prepare:

1- Thin smear for direct microscopic examination aiming at detection of parasitic stages, mainly cysts and eggs.

2- Permanent stained smears using Modified Trichrome stain (MTS) (Weber green) for detection of microsporidia spores.

* A small part of each specimen was stored without any additives at -20°C in eppendorff tubes for subsequent use in molecular diagnosis.

2.1.2. Urine samples:

All samples were subjected to centrifugation and the sediment was divided into 2 portions:

1- Part used for preparing permanent stained smears using MTS (Weber Green) for detection of microsporidia spores.

2- Part was stored at -20°C in Eppendorff tubes for subsequent use in molecular diagnosis.

2.2. Molecular diagnosis:

Molecular diagnosis by PCR involves three main steps:

Extraction of genomic DNA: from stool and urine samples using commercially-available kits.

DNA amplification and cycling protocol by allele specific PCR.

Detection of and visualization of the amplified DNA: using agarose gel electrophoresis and ultra violet light transillumination.

2.2.1. DNA extraction:

* Extraction of genomic DNA from stool specimens using FavorPrep Stool DNA Isolation Mini Kit:

The FavorPrep Stool DNA Isolation Kit was designed for isolation of high quality total DNA from 50~200 mg of fresh or frozen stool sample.

* Extraction of genomic DNA from urine specimens using FitAmpUrine DNA Isolation Kit.

The *FitAmp*TM Urine DNA Isolation Kit allows isolation of DNA size from 100 bp to 20 kb; DNA quantity from 1 ng to 2 µg, optimal at between 10 ng and 1 µg.

2.2.2. DNA amplification and PCR:

Principle:

Extension of the primers by thermo-stable DNA polymerase enzyme was done using deoxynucleotide triphosphates (dNTP) at 72 °C. Repeating these steps many times results in exponential increase in the amount of target DNA [10]. Hybaid thermal cycler (Promega Corporation, USA) was used in amplification.

Materials used for DNA amplification:

* 2X Taq Master Mix (VivantisTechnologies, Malaysia):

It comprises: 4x625µl 2X Taq Master Mix consists of:

A) Taq DNA polymerase in reaction buffer: 0.05 units/µl.

B) MgCl₂: 3mM

C) Deoxynucleotide triphosphates (dNTPs) :(dATP, dCTP, dGTP,dTTP): 0.4 mM of each.

* Primers (VivantisTechnologies, Malaysia):

Two primers were used for diagnosis of *E.bieneusi* and *Encephalitozoon* [11]. The primers were used to amplify specifically conserved regions of SSU rRNA, interms of positions 4 to 23 for *E.bieneusi* [GenBank AF023245]:5'-CAGGTTGATTCTGCCTGACG, as the forward primer (FP), and positions 263 to 244 for *E. bieneusi* 5'-ATCTCTCAGGCTCCCTCTCC, as the reverse primer (RP).

25u of the previous mixture was inserted in the thermal cycler and the thermal profile was adjusted as follow:

Initial denaturation at 94°C for 5 minutes, then 35 cycles of amplification consisting of denaturation at 94°C for 30 seconds, annealing at 55°C for30 seconds and extension at 72°C for 30 seconds. Final elongation was done for 2 minutes at 72°C.

2.2.3. Detection of the amplified DNA using 2% agarose gel electrophoresis:

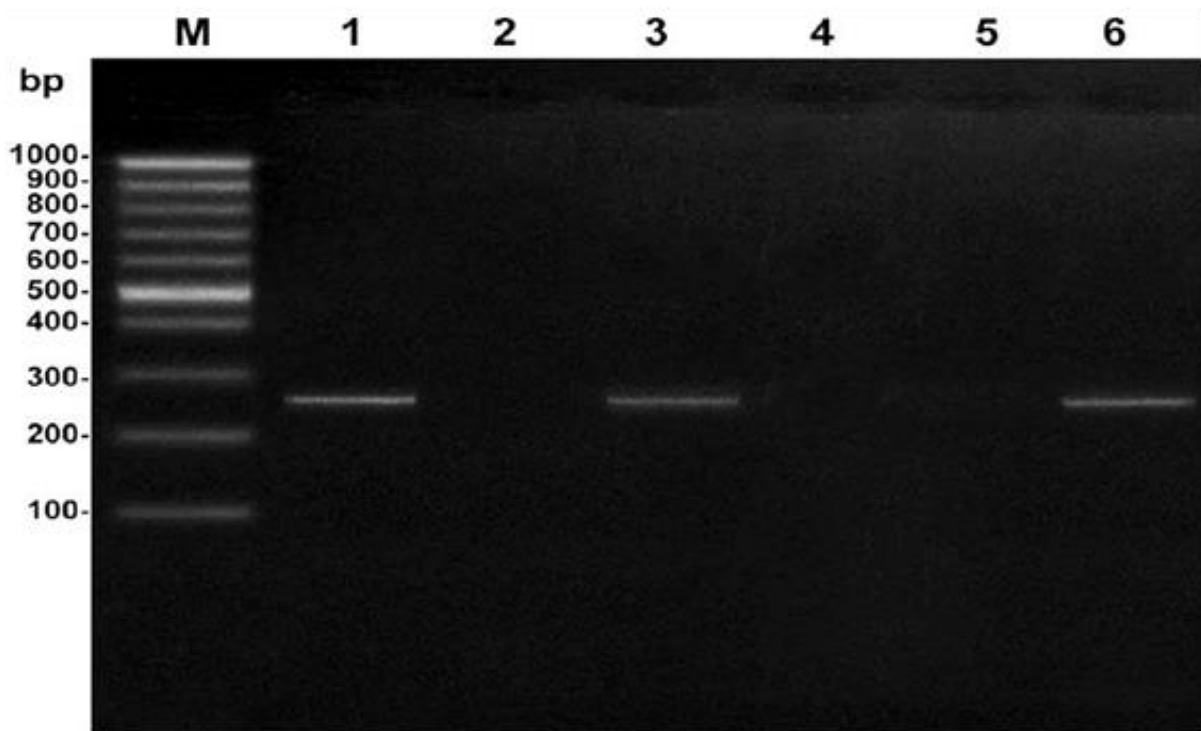


Figure 1: An ethidium bromide stained agarose gel electrophoresis showing the extended PCR product of Microsporidia.

Lane M : DNA maker (100bp ladder)

Lane 1 : Positive control

Lane 2 : Negative control

Lane 3, 6 : Positive cases of microsporidiosis showing the PCR product of expected size (260 bp).

Lane 4, 5 : Negative cases of microsporidiosis showing no PCR product.

2.3. Statistical analysis:

Data were statistically described in terms of mean and standard deviation, median and range or frequencies (number of cases) and percentages when appropriate. Comparison of numerical variables between the study groups was performed using Student's *t*-test for independent samples. Comparison of numerical variables was performed using paired *t*-test. $P < 0.05$ was considered to be statistically significant. Association between qualitative data was done using Chi Square (X^2) test. Correlation between various variables was done using Pearson moment correlation equation. All statistical calculations were performed using computer programs SPSS (Statistical Package for the Social Science; SPSS Inc., Chicago, IL, USA) version 15 for Microsoft Windows.

III. RESULTS:

This study included 50 chronic renal failure patients; their ages ranged from 18 to 78 years with mean of 42.54 years. Our patients were 29 males and 21 females. The study also included 30 - age and sex matched - healthy subjects that served as a control group.

Table 1: Age distribution in relation to sex in terms of mean and standard deviation in the study group

Sex	no	%	Mean of age	Std deviation
Male	29	58 %	42.96	15.88
Female	21	42 %	41.95	16.24
Total	50	100 %	42.54	15.87

Using PCR, microsporidiosis was positive in 2 stool samples (4%) of the study group. These 2 samples were also positive microscopically by MTS staining, another case is positive by MTS alone. No microsporidia spores were detected in the urine samples. As regards control group, no microsporidia spores were detected in their stool or urine samples. The three cases of microsporidiosis are presenting with diarrhea.

Table 2: Comparison between results of PCR and examination of MTS smears for microsporidiosis in the study group (n=50)

			PCR		Total
			-ve	+ve	
MTS stain	-ve	No	47	0	47
		% within PCR	97.9 %	0 %	94.0 %
	+ve	No	1	2	3
		% within PCR	2.1 %	100 %	6.0 %
Total		No	48	2	50

Table3: Associated clinical manifestations in the study group

Symptoms	Total number n=50	Microsporidiosis n=3
	Frequency [n. (%)]	Frequency [n. (%)]
Diarrhea	23 (46%)	3 (100%)
Colic	13 (26%)	1 (33.3%)
Fever	2 (4%)	0 (0%)

IV. DISCUSSION

Microsporidiosis is an emerging and opportunistic infection caused by microsporidia affecting mainly immunocompromised patients [12]. A high incidence of infection is found in uraemic patients and infections remain the second most frequent cause of death [13].

In the study group, microsporidiosis was revealed in 2 stool samples (4%) using both PCR and MTS. An additional 1 sample was positive only by MTS staining. No microsporidia spores were detected in the urine samples. As regards control group, no microsporidia spores were detected in their stool or urine samples.

These results should not be considered representative for the prevalence of microsporidiosis among the group studied. In fact, larger number of patients is needed for determination of the prevalence. The small number of cases diagnosed as microsporidiosis limits the generalization of the findings concerning age and sex distribution or those concerning the occurrence of the clinical parameters. Also this small number of cases limited the statistical power of the analysis and affected the presence of significant association between microsporidia and positive findings.

Few studies on the prevalence of microsporidia in the chronic renal failure patients in Egypt were carried out.

In agreement with the present study as regards the examined stool samples, a similar rate of infection with microsporidia was reported in a study done by [14] who reported a rate of 4.4% for microsporidiosis in immunosuppressed patients. Similarly, [15], detected intestinal microsporidiosis in 4.8% of examined pediatric cancer patients in Egypt using both PCR and acid fast trichrome stain. In Egypt, among studies that have been performed on chronic renal failure cases is that done by [16] on fresh stool samples obtained from patients suffering from CRF and attending renal dialysis unit of Sohag University Hospital using acid fast stain. In this study the percentage of microsporidiosis was 2% which is lower than that detected in the present study.. [17] also reported intestinal microsporidiosis in 2% of immunocompromised patients divided into different groups, group of them with CRF. Similarly, low rate of infection was revealed by [18] who reported a rate of 2.7% for microsporidiosis in immunosuppressed patients.

In another study done by **Ali et al. [19]**, on fresh stool samples from patients suffering from CRF and attending the dialysis unit of Zagazig University, the rate of 7% of infection with microsporidia was revealed.

A higher detection rate was recorded by [20] who reported a rate of 17% among cancer patients.

The variability in the rates of positive cases obtained in the previous studies may be due to environmental, seasonal, geographical factors and or differences in sensitivity of diagnostic techniques used in each study. Also, this may be due to difference in the experience of the researchers, especially the spores are very small [20]. As regards the urine samples, [22] in Spain found no microsporidial spores in 127 examined urine samples collected from HIV positive children using MTS and PCR. The same study revealed only one positive stool

sample. On the other hand, other studies reported variable detection rate of microsporidia in urine samples. [23] detected microsporidial spores in only one sample (2.5%) out of the examined 40 human urine samples using MTS. Higher results were reported by [24] who found microsporidia spores in 50% of urine samples of AIDS patients using Giemsa stain. In other studies, microsporidial spores were detected microscopically in 100% of all examined human urine samples collected from AIDS patients [25- 27]. This high incidence rate may be due to the role played by AIDS disease acting as predisposing cause for microsporidiosis.

Concerning demographic data of the two PCR positive cases, one case was female, while the other was male . The third case, diagnosed positive only by MTS, was female. Also in the present study, out of patients suffering from diarrhea, (13%) were infected by microsporidia.

Many studies detected no significant sex differentiation for microsporidiosis [28- 30]. Alternatively, other studies showed statistical significance. [31] found that percentage of infected female (42.6%) was significantly higher than males, while [21] observed high prevalence rate of microsporidiosis in males. The occurrence of chronic diarrhea and other gastrointestinal symptoms as colic and anorexia in microsporidia positive patients were reported by some studies [21, 32, 33].

In contrast, others suggested that most microsporidial infections are asymptomatic [29, 34].

Also, [30] reported that prevalence of microsporidiosis among immunocompetent people was remarkably high (67.5%) and stated that no apparent correlation between diarrhea and microsporidial infection.

Transient correlation between detection of microsporidia in stool and gastrointestinal symptoms, suggests that microsporidia infection may cause clinical symptoms during the early stage of infection that resolve even though the microsporidia may persist [33].

[35] stated that the absence of significant association between microsporidia and diarrhea may be recorded if the infection was not sufficiently intense to cause disease and the association may be detected after several stool examinations.

V. COMPETING INTERESTS

The authors declare that they have no competing interests.

VI. ACKNOWLEDGEMENTS

The authors would like to thank Samar Adel Yousry for participating in laboratory work and Omar Abd-Elrahman Khalifa for editing the manuscript.

REFERENCES

- [1] Didier ES. (1998): Microsporidiosis. Clin. Infect. Dis. 27(1): 1-7.
- [2] Norhayati M., Azlin M., Al-Mekhlafi MH., Anisah N., Nor Aini U., Fatmah MS., and Rozlida AR. (2008): A preliminary study on the prevalence of intestinal microsporidiosis in patients with and without gastrointestinal symptoms in Malaysia. Trans. R. Soc. Trop. Med. Hyg. 102(12):1274–1278.

-
- [3] Stark D., Barratt JL., van Hal S., Marriott D., Harkness J., and Ellis JT. (2009): Clinical significance of enteric protozoa in the immunosuppressed human population. *Clin. Microbiol. Rev.* 22(4): 634-650.
- [4] Anane S. and Attouchi H. (2010): Microsporidiosis: Epidemiology, clinical data and therapy. *Gastroenterol. Clin. Biol.* 34(8- 9): 450-464.
- [5] Didier ES. (2005): Microsporidiosis: an emerging and opportunistic infection in humans and animals. *Acta Tropica.* 94(1): 61-76.
- [6] Bern C., Kawai V., Vargas D., Rabke-Verani J., Williamson J., Chavez-Valdez R., Xiao L., Sulaiman I, Vivar A, Ticona E, Navincopa M, Cama V, Moura H, Secor WE, Visvesvara G, Gilman RH. (2005): The epidemiology of intestinal microsporidiosis in patients with HIV/AIDS in Lima, Peru. *J. Infect. Dis.* 191(10): 1658-1664.
- [7] Garcia LS. (2002): Laboratory identification of the microsporidia. *J. Clin. Microbiol.* 40(6):1892–1901.
- [8] Ghosh K. and Weiss LM. (2009): Molecular diagnosis tests for microsporidia .
(Review Article). *Interdiscip. Perspect. Infec. Dis.* Article ID: 926521.
- [9] Sokolova OI., Demyanov AV., Bowers LC., Didier ES., Yakovlev AV., Skarlato SO., and Sokolova YY. (2011): Emerging Microsporidian Infections in Russian HIV-Infected Patients. *J. Clin. Microbiol.* 49(6): 2102–2108.
- [10] Williams JF. (1989): Optimization strategies for the polymerase chain reaction. *Biotechniques.* 7(7):762-769.
- [11] Notermans DW., Peek R., De Jong MD., Wentink-Bonnema EM, Boom R, van Gool T. (2005): Detection and identification of *Enterocytozoon bienewsi* and *Encephalitozoon* species in stool and urine specimens by PCR and differential hybridization. *J. Clin. Microbiol.* 43(2): 610–614.
- [12] Galvan AL., Sanchez AM., Valentin MA. Henriques-Gil N, Izquierdo F, Fenoy S, and del Aguila C. (2011): First cases of microsporidiosis in transplant recipients in Spain and review of the literature. *J. Clin. Microbiol.* 49(4): 1301- 1306.
- [13] Gimdt M., Sester U., Sester M., Kaul H., and Köhler H. (1999): Impaired cellular immune function in patients with end-stage renal failure. *Nephrol. Dial. Transplant.* 14(12): 2807-2810.
- [14] Hammouda NA., Sadaka HA., El-Gebaly WM., and El-Nassery SM. (1996): Opportunistic intestinal protozoa in chronic immunosuppressed patients. *J. Egypt Soc. Parasitol.* 26(1): 143-153.
- [15] El-Mahallawy H., Zaki MM., El-Arousy M., Shalabi L., and Mansour T.
(2011): Diagnosis of intestinal microsporidiosis in paediatric oncology patients in Egypt using modified acid fast trichrome staining versus PCR. *Acta Parasitol.* 56(4): 348–352.
- [16] El-Nadi N. and Taha A. (2004): Intestinal parasites detected haemodialysis patients in Sohag University Hospitals. *El-Minia Medical Bulletin.* 15(2): 233-240.
- [17] Baiomy AM., Mohamed KA., Ghannam MA., Shahat SA., and Al-Saadawy AS. (2010): Opportunistic parasitic infections among immunocompromised Egyptian patients. *J. Egypt Soc. Parasitol.* 40(3): 797-808.
- [18] Abaza SM., Makhlof LM., El-Shewy KA., and El-Moamly AA. (1995): Intestinal opportunistic parasites among different groups of immunocompromised hosts. *J. Egypt Soc. Parasitol.* 25(3): 713-727.
- [19] Ali MS., Mahmoud LA., Abaza BE., and Ramadan MA. (2000): Intestinal spore-forming protozoa among patients suffering from chronic renal failure. *J. Egypt Soc. Parasitol.* 30(1): 93-100.
- [20] El Sobky MM. and El Nahas NS. (2012): Detection and Differentiation between

Enterocytozoon bieneusi and *Encephalitozoon intestinalis* Species in Cancer Patient's Stools Using PCR Compared with Different Staining Methods. PUJ. 5(1): 19-26.

[21] Endeshaw T., Kebede A., Verweij JJ., Zewide A., Tsige K., Abraham

Y., Wolday D, Woldemichael T, Messele T, Polderman AM, Petros B. (2006): Intestinal microsporidiosis in diarrheal patients infected with human immunodeficiency virus-1 in Addis Ababa, Ethiopia. Jpn. J. Infect. Dis. 59(5):306- 310.

[22] Del Aguila C., Navajas R., Gurbindo D., Romas JT., Mellado MJ, Fenoy S., Munoz Fernandez MA., Subirats M., Ruiz J., and Pieniazek NJ. (1997): Microsporidiosis in HIV-Positive Children in Madrid (Spain). J. Eukariot. Microbiol. 44(6): 84S-85S.

[23] Abreu-Acosta N., Lorenzo-Morales J., Leal-Guio Y., Coronado- Alvarez N., Foronda P., Alcoba-Florez J., Izquierdo F, Batista-Díaz N, Del Aguila C, Valladares B. (2005): *Enterocytozoon bieneusi* (microsporidia) in clinical samples from immunocompetent individuals in Tenerife, Canary Islands, Spain. T. Royal Soc. Trop. Med. Hygiene 99(11): 848-55.

[24] Didier ES., Didier PJ., Friedberg DN., Stenson SM., Orenstein JM., Yee RW., Tio FO., Davis RM., and Vossbrinck C. (1991): Isolation and characterization of a new human microsporidian, *Encephalitozoon hellem* (n. sp.), from three AIDS patients with keratoconjunctivitis. J. Infect. Dis. 163(3): 617-621.

[25] Ryan NJ., Sutherland G., Coughlan K., Globan M, Doultree J, Marshall J, Baird RW, Pedersen J, Dwyer B. (1993): A new trichrome-blue stain for detection of microsporidial species in urine, stool, and nasopharyngeal specimens. J. Clin. Microbol. 31(12): 3264-3269.

[26] Matos O., Lobo ML., Goncalves L., and Antunes F. (2002): Diagnostic use of 3 techniques for identification of spores among AIDS patients in Portugal. Scand. J. Infect. Dis. 34(8): 591-593.

[27] Menotti J., Cassinat B., Porcher R., Sarfati C., Derouin F., and Molina JM. (2003): Development of a real-time polymerase-chain-reaction assay for quantitative detection of *Enterocytozoon bieneusi* DNA in stool specimens from immunocompromised patients with intestinal microsporidiosis. J. Infect. Dis. 187(9): 1469-1474.

[28] Munghin M., Suwannasaeng R., Naaglor T., Areekul W., and Leelayoova S. (2001): Asymptomatic intestinal microsporidiosis in Thai orphans and child-care workers. Trans. R. Soc. Trop. Med. Hyg. 95(3): 304-306.

[29] Angela R., and Suresh K. (2007): microsporidia in stools from cancer patients. Res. J. Med. Sci. 1(2): 88-90.

[30] Nkinin SW., Asonganyi T., Didier ES., and Kaneshiro ES. (2007): Microsporidian infection is prevalent in healthy people in Cameroon. J. Clin. Microbiol. 45(9): 2841-2846.

[31] Mor SM., Tumwine JK., Naumova EN., Ndeezi G. and Tzipori S. (2009):

Microsporidiosis and Malnutrition in Children with Persistent Diarrhea, Uganda. Emerg. Infect. Dis. 15(1): 49-52.

[32] Tumwine JK., Kekitiinwa A., Bakeera-Kitaka S., Ndeezi G., Downing R., Feng X., Akiyoshi DE., and Tzipori S. (2005): Cryptosporidiosis and microsporidiosis in Ugandan children with persistent diarrhoea with and without concurrent infection with the human immunodeficiency virus. Am. J. Trop. Med. Hyg. 73(5): 921-925.

[33] Wichro E., Hoelzl D., Krause R., Bertha G., Reinthaler F., and Wenisch C. (2005): Microsporidiosis in travel-associated chronic diarrhoea in immunocompetent patients. Am. J. Trop. Med. Hyg. 73(2): 285-287.

[34] Rabeneck L., Gyorkey F., Genta RM., Gyorkey P., Foote L., and Risser JM. (1993): The role of microsporidia in the pathogenesis of HIV-related chronic diarrhea. Ann. Intern. Med. 119: 895-899.

[35] Chacin-Bonilla L., Panunzio AP., Monsalve-Castillo FM., Parra-Cepeda IE., and Martinez R. (2006): Microsporidiosis in Venezuela: prevalence of intestinal microsporidiosis and its contribution to diarrhoea in a group of human immunodeficiency virus-infected patients from Zulia State. Am. J. Trop. Med. Hyg. 74(3): 482-486.